

## Monophasic action potential-like ECG

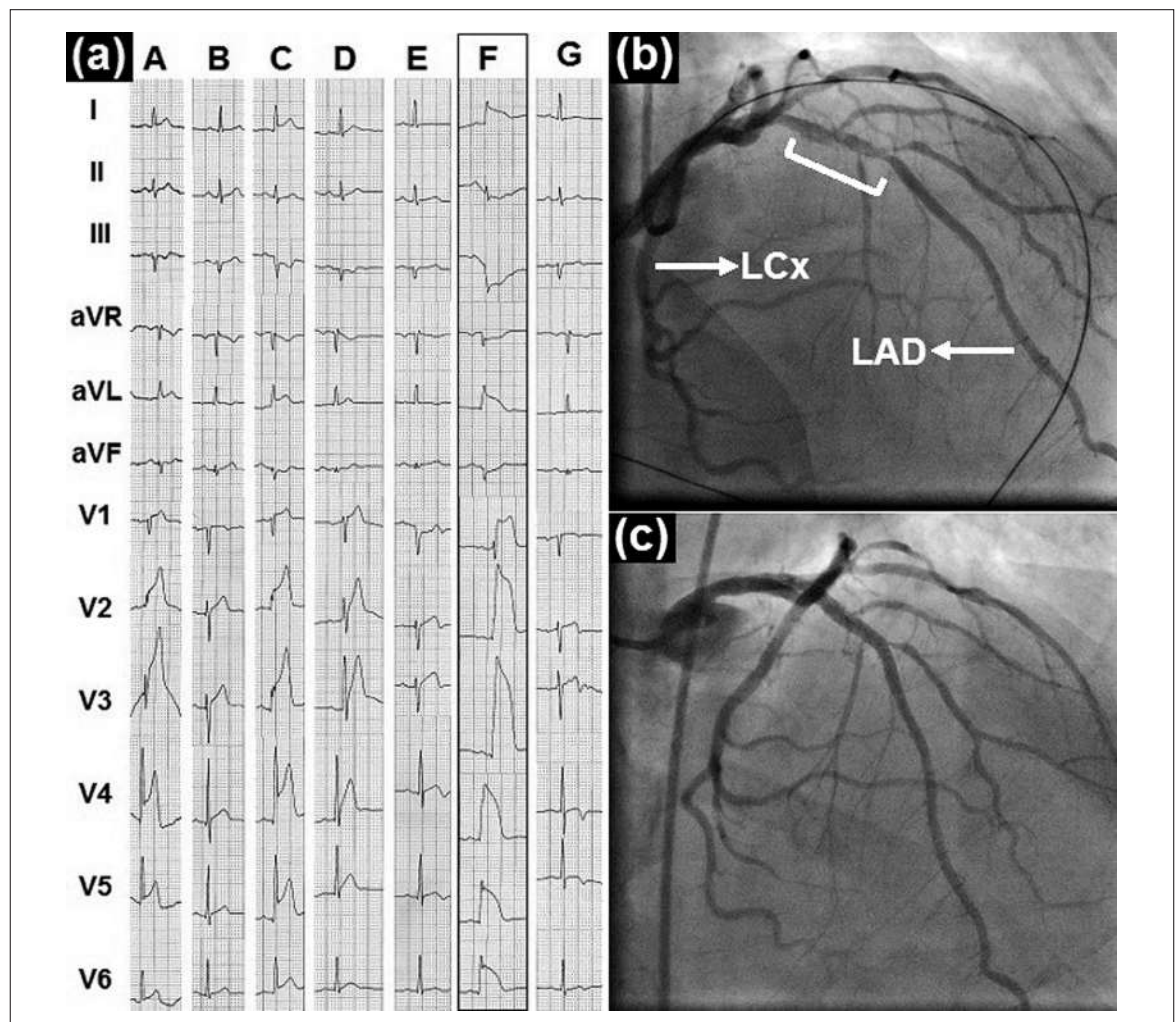
# A rare electrocardiographic presentation of acute ischaemic heart disease

Andreas Y. Andreou

Department of Cardiology, Limassol General Hospital, Limassol, Cyprus

A 56-year-old male smoker with dyslipidaemia was admitted because of a 20-minute history of substernal chest pain and ST-segment elevation (STE) in the

anterolateral leads (fig. 1a). He had no previous episodes of chest pain either at rest or during exercise. His pain rapidly subsided with complete STE resolution



**Figure 1:** (a) Electrocardiogram (ECG) at A was recorded on patient's presentation and ECGs at C and F were recorded during episodes of recurrent angina. All three ECGs display ST-segment elevation (STE) in the anterolateral leads while the ECG at F is notable for a monophasic action potential-like STE pattern. ECGs at B and E show complete STE resolution after the first and second episode of angina, respectively. ECG at D was recorded immediately after successful resuscitation from ventricular fibrillation and shows a regression of the STE suggesting reperfusion. ECG at G was recorded on discharge and shows preserved anterior QRS forces. (b) Baseline angiographic view of the left anterior descending (LAD) artery showing a non-tight proximal lesion (bracket) with intraluminal lucencies suggestive of thrombus. The left circumflex (LCx) artery is also shown. (c) Angiographic view of the LAD artery after stent angioplasty.

when treated with aspirin and an intravenous infusion of isosorbide dinitrate. At 50 minutes, he developed recurrent chest pain and STE in the anterolateral leads; therefore, he was treated with escalating nitrate doses and tenecteplase thrombolysis. Ten minutes later he developed ventricular fibrillation and an electrocardiogram (ECG) recorded immediately after successful defibrillation displayed a reduction in the amplitude of the ST segment suggesting reperfusion; at 60 minutes complete STE resolution was documented. The patient was stable for 75 minutes, when he had recurrent chest pain with marked STE in the anterolateral leads resembling a monophasic action potential (MAP). Emergency coronary angiography revealed a patent left anterior descending artery with a proximal thrombotic lesion (fig. 1b). During angiography the patient was pain free and, given the angiographic findings, we hypothesised that the STE resolved. After aspiration thrombectomy, a 3.0 mm × 26 mm drug-eluting stent was uneventfully deployed across the lesion (fig. 1c). The discharge ECG showed preserved anterior QRS forces (fig. 1a), whereas echocardiography showed hypokinesia involving only the apex and an ejection fraction of 55%. The patient remained asymptomatic and event-free 2 years after the intervention.

The MAP-like STE ECG pattern is a rarely encountered manifestation of acute transmural ischaemia that has been described during the hyperacute phase of myocardial infarction, attacks of coronary vasospastic angina and exercise ECG testing [1, 2]. It comprises R waves with increased amplitude and duration, markedly elevated ST segments and prominent T waves that merge to form monophasic curves; it has been attributed to late unopposed depolarisation of a severely ischaemic myocardial territory secondary to marked focal slowing of transmural conduction [3]. Conduction delay is due to fast Na<sup>+</sup> channel inactivation and reduced availability caused by ischaemia-induced hyperkalaemia and the associated sarcolemma depolarisation [4]. The rapid resolution of the first and second episode of STE with intravenous nitrate therapy together with the non-tight culprit lesion documented

here, suggested that coronary spasm played the predominant role in the production of transient coronary occlusion. Spasm might have triggered rupture of a vulnerable plaque at the culprit site with subsequent thrombosis, which might have contributed to the persistence of STE episodes as a result of a vasoconstrictor response [5]. Yet, in the absence of a previous history of coronary vasospastic angina or angiographic proof of spasm, we considered coronary thrombus undergoing spontaneous partial lysis as an alternative scenario for our patient's presentation. The MAP-like STE ECG pattern recorded upon the inception of the third ischaemic episode suggested a more severe degree of ischaemia, which might be attributed to reduced ability of the microvasculature to dilate and recruit collaterals; that is, decreased coronary flow reserve secondary to transient depletion of vasoactive substances (primarily adenosine) caused by the preceding episodes of ischaemia and reperfusion [6]. This type of ECG has been found to predict the occurrence of ventricular fibrillation early (within 6 hours) after the onset of acute myocardial infarction with specificity greater than 95% [7].

#### References

- 1 Madias JE. The "giant R waves" ECG pattern of hyperacute phase of myocardial infarction. A case report. *J Electrocardiol.* 1993;26(1):77–82.
- 2 Testa-Fernández A, Rios-Vazquez R, Sieira-Rodríguez-Moret J, Franco-Gutierrez R, Peña-Gil C, Pérez-Fernández R, et al. "Giant R wave" electrocardiogram pattern during exercise treadmill test: A case report. *J Med Case Reports.* 2011;5:304.
- 3 Madias JE. Prinzmetal's work and the "Sclarovsky-Birnbaum ischemia score" for acute myocardial infarction: a parallel in systematizing electrocardiographic knowledge. *J Electrocardiol.* 2009;42(1):27–34.
- 4 Cordeiro JM, Mazza M, Goodrow R, Ulahannan N, Antzelevitch C, Di Diego JM. Functionally distinct sodium channels in ventricular epicardial and endocardial cells contribute to a greater sensitivity of the epicardium to electrical depression. *Am J Physiol Heart Circ Physiol.* 2008;295(1):H154–62.
- 5 Wang LX, Lü SZ, Zhang WJ, Song XT, Chen H, Zhang LJ. Coronary spasm, a pathogenic trigger of vulnerable plaque rupture. *Chin Med J (Engl).* 2011;124(23):4071–8.
- 6 Vanhaecke J, Flameng W, Borgers M, Jang IK, Van de Werf F, De Geest H. Evidence for decreased coronary flow reserve in viable postischemic myocardium. *Circ Res.* 1990;67(5):1201–10.
- 7 Aizawa Y, Jastrzebski M, Ozawa T, Kawecka-Jaszcz K, Kukla P, Mituma W, et al. Characteristics of electrocardiographic repolarization in acute myocardial infarction complicated by ventricular fibrillation. *J Electrocardiol.* 2012;45(3):252–9.

#### Correspondence:

Andreas Y. Andreou, MD  
Department of Cardiology  
Limassol General Hospital  
Nikeas street 3304, Pano  
Polemida, PO Box 56060  
Limassol  
Cyprus  
y.andreas[at]yahoo.com