

Presented at the Swiss Society of Cardiology Congress 2018 in Basel

Forty years of percutaneous coronary intervention

Bernhard Meier

Cardiovascular Department, University Hospital Bern, Bern, Switzerland



Percutaneous coronary intervention (PCI) probably represents the most important contribution to world medicine of all time coming out of Switzerland.

The story of percutaneous coronary intervention (PCI) in Zurich, Switzerland, as well as in the rest of the world, basically started in 1969 when the German Andreas Grüntzig joined the University Hospital of Zurich, Switzerland, at the time called the Kantonsspital. Grüntzig was intrigued by the textbook on Differential Diagnosis in Internal Medicine written by Robert Hegglin, the head of internal medicine. The tragic demise of Hegglin a few months after Grüntzig's arrival in a way catalysed the development of PCI. Alfred Bollinger, an angiologist, took over as Grüntzig's mentor. Grüntzig's rucksack already contained experience in the epidemiology of cardiovascular disease, acquired in England, and some practical knowledge of peripheral angiography from the Ratschow Hospital in Darmstadt, Germany. During a thorough training in all aspects of angiology, a discipline pertaining to peripheral vessels as cardiology pertains to the heart, Grüntzig developed several interesting ideas that were, however, not further pursued, before he came up with balloon angioplasty of peripheral vessels, later modified to PCI [1]. Claudicometry was one of his earlier ideas. It quantified the degree of muscle ischaemia during exercise in patients with peripheral artery disease by photometrically measuring the duration of relaxation in the Achilles tendon reflex. Another was a crude endarterectomy device constructed of a wire with C-shaped tip. The stretched wire was introduced through a plastic catheter to a position distal to an obstruction and then rotated with a household drill and pulled back through the obstruction, to carve a wider tunnel.

Balloon angioplasty came about when Grüntzig was introduced by Eberhardt Zeitler to the Dotter technique to open obstructed peripheral vessels in a bougie-like fashion. Grüntzig saw potential in the technique, but no future in its (then) current version. The idea of inserting a small-calibre balloon that was inflated to its full diameter only within the stenosis and then deflated before removal was simple, but was dependent on form-constant balloon material, which Grüntzig

found with the help of a plastics expert at the Swiss Technical University situated right across the University Hospital [2]. Serendipity kicked in when Grüntzig caught the eye of Wilhelm Rutishauser, the chief of cardiology. Seeing Grüntzig as a prodigy, even through the mist created by most of his colleagues badmouthing Grüntzig, Rutishauser wanted that talent and balloon angioplasty for cardiology, in particular for modern society's new plague, coronary artery disease (CAD). Grüntzig more than fulfilled his promise. Despite the lack of proper training in cardiology, he climbed the ladder to senior staff member within a few months and found the means to have the handcrafted balloon catheters for peripheral arteries miniaturised and professionally produced by a small company, called Schneider Medintag. Animal experiments in 16 dogs with the help of Marko Turina, the right hand of the chief of cardiovascular surgery, Åke Senning, were successful, allowing the start of clinical application in humans. In eight dogs, the coronary arteries were ligated and balloon dilated immediately, and in eight dogs, balloon dilation was deferred by 1 week after creating a stenosis by ligation. Of the latter dogs, two were left alive for 4 weeks, to histologically document the internal healing process in the coronary arteries [3].

It was more than a year until a suitable patient for the world's first PCI was finally found. Grüntzig looked for a single stenosis in the proximal segment of a major coronary artery. At the time, coronary angiography was typically only performed when long periods of treatment with a combination of antianginal drugs had failed or several myocardial infarctions had occurred. A single lesion was hard to find in such patients. It was again serendipity that brought me into contact with Grüntzig in 1976 during my internship in angiology. It also let me find this first patient on the ward of internal medicine I was working at. I wrote the now historical discharge letter on this patient. He was 38 years of age, smoked heavily and had a history of a fortnight of unstable and menacing angina pectoris, which led to emergency

hospitalisation in a peripheral hospital. The referral to our tertiary hospital was decided upon after his angina did not abate and his CAD was documented with a positive exercise stress test resulting in severe angina, ST-segment elevation in the electrocardiogram (ECG), and ventricular tachycardia. Nowadays, such a patient would be hauled immediately to a catheterisation laboratory and an exercise stress test would be considered malpractice. Notably, the today unknown radiologist who performed coronary angiography on this patient on 14 September 1977, described several lesions and called the situation multivessel disease, although there was just a single lesion in the proximal left anterior descending coronary artery. The subsequent history led to several publications [4–6]. It is further remarkable that an exercise stress test 3 days after the intervention still showed some transient ST-segment elevation in the ECG, albeit less marked than before the intervention and not accompanied by ventricular tachycardia, with only minimal angina, and that the patient was discharged on a vitamin K antagonist. Acetylsalicylic acid had just been recognised as a platelet inhibitor, but its use was not yet standard in CAD at the time. Alongside PCI, Grüntzig also introduced live courses into cardiovascular medicine, a format hitherto only known in the field of orthopaedic surgery. The first

such course offered a varied and interesting programme, but elicited little interest (fig. 1). Over subsequent decades, the standard PCI gear, consisting of balloon catheter, coronary guidewire and guiding catheter, dramatically improved and the required access hole diminished from 12F (the outer dimension of a 10F sheath) to 5F (sheathless access with a 5F guiding catheter [7]). Concomitantly, resolution of fluoroscopy increased dramatically and the advent of easy and digitally enhanced replay and still-frame capabilities, at the same (or even better) quality of the initial 35 mm cine-films, further facilitated intervention. The only instrumental addition to the balloon as therapeutic tool was the coronary stent, introduced in 1986 [8]. At first it mainly reduced the risk of abrupt vessel closure with subsequent infarction or need for emergency coronary bypass surgery. Restenosis was also reduced in absolute numbers but restenotic lesions within a stent, which still occurred regularly, were more difficult to treat than the restenotic lesions after balloon angioplasty. After the introduction of drug-eluting stents and further refinements in stent design, the initial threat of thrombotic stent occlusion (forfeiting a late outcome benefit of stenting over balloon angioplasty) was virtually abolished and restenosis was reduced to almost an insignificant level. For 10 years (2006–16), there was a prevailing misconception that the early generation drug-eluting stents were riskier than bare-metal stents regarding stent thrombosis. This was based on the fact that the initial drug-eluting stents had a higher risk of stent thrombosis after the first year than bare-metal stents. The fact that the early risk of stent thrombosis was lower with drug-eluting stents (from their first generation) than with bare-metal stents was ignored. The paradoxical recommendation to use heavier antiplatelet treatment with drug-eluting stents for the first year was almost generally observed and to some extent still is nowadays. Current drug-eluting stents have a low risk of stent thrombosis, at any stage of follow-up and irrespective of the antiplatelet regimen, and a single modern antiplatelet agent such as prasugrel or ticagrelor is probably sufficient. If combined with acetylsalicylic acid, a couple of weeks of double antiplatelet therapy should be enough. The later preventive antiplatelet therapy targets spontaneous plaque rupture rather than the implanted stents and should therefore be tailored to the plaque burden of the patient. Triple anticoagulation therapy should not be used in any patient. It is likely that modern anticoagulants, the likes of apixaban, dabigatran, edoxaban, or rivaroxaban, provide good protection against both stent thrombosis and spontaneous plaque rupture. However, randomised data are lacking.

Monday, August 7, 1978		Wednesday, August 9, 1978	
9.00 – 9.30 a.m.	Registration	9.00 – 11.00 a.m.	PTCA of LAD (L.O., 1924)
9.30 – 10.00 a.m.	Welcoming address and introduction	11.00 – 1.00 p.m.	PTA of femoral stenosis (Z.D., 1906) no transmission into the lecture-room; contact the secretary
10.00 – 12.00 a.m.	Percutaneous transluminal coronary angioplasty (PTCA) of LAD-stenosis (C.A., 1947)	1.00 – 2.00 p.m.	L u n c h
12.00 – 1.00 p.m.	Discussion	2.00 – 4.00 p.m.	PTCA of LAD (M.V., 1927)
1.00 – 2.00 p.m.	L u n c h	4.00 – 5.00 p.m.	Review of cases, reports from Lenox-Hill Hospital, New York
2.00 – 4.00 p.m.	PTCA of LAD (B.K., 1937)		
4.00 – 5.00 p.m.	Review of cases, discussion		
Tuesday, August 8, 1978		Thursday, August 10, 1978	
8.00 – 10.00 a.m.	PTCA of RCA (K.H., 1935)	8.00 – 10.00 a.m.	PTCA of RCA (K.A., 1921)
10.00 – 12.00 a.m.	PTA of femoral occlusion (H.F., 1926)	10.30 – 12.00 a.m.	PTA of renal artery (C.A., 1931)
12.00 – 1.00 p.m.	Discussion	12.00 – 1.00 p.m.	Final discussion and conclusions
1.00 – 2.00 p.m.	L u n c h	2.45 p.m.	Bus departure to Einsiedeln
2.00 – 4.00 p.m.	PTCA of coronary bypass graft (M.H., 1923)	4.15 – 6.00 p.m.	Visit of the Monastery, Einsiedeln
4.00 – 5.00 p.m.	Review of cases, reports from St. Mary's Hospital, San Francisco	6.30 – 9.00 p.m.	Dinner at the Hotel Pfauen, Einsiedeln
7.00 – 11.00 p.m.	Boat excursion Lake of Zurich (Dinner on board) Boat departure: Bürkliplatz		

Figure 1: First life course in interventional cardiology in August 1978, organised and conducted by Grüntzig (courtesy of Maria Schlumpf).

A total of 37 delegates registered but only 28 showed up. The programme was already quite diversified, with percutaneous coronary intervention (PCI), at the time called PTCA (percutaneous transluminal coronary angioplasty), of two left anterior descending coronary artery (LAD) stenoses, percutaneous transluminal angioplasty (PTA) of a femoral occlusion, PTCA of a stenosed coronary artery venous bypass graft, and PTA of a renal artery stenosis (cases marked by red frames).

PCI now justifiably includes stent implantation by default in the light of the excellent performance of modern stents. All the other complements or replacements of PCI were either failures or at best are add-ons with little influence on the final result. They are displayed in fig. 2. Two currently overrated and hence overused techniques in PCI deserve special mention: the use of fractional flow reserve (FFR) or instantaneous wave-free ratio (iFR) and the radial approach.

FFR has been around for more than two decades [9]. However, it only caught the fancy of the nonresearch-oriented interventional cardiologist after publication of a trial showing that FFR-guided PCI (dilating only

stenoses with an FFR <0.8, which identifies a haemodynamically significant stenosis) had a better prognosis than angiographically guided PCI [10]. This made sense only if a high risk were ascribed to PCI of mild stenoses, higher even than it was with bare-metal stents and their significant risk for stent thrombosis. With the current innocuous and highly successful drug-eluting stents, guiding PCI by FFR or iFR makes no sense at all and even puts the patient at a risk of increased mortality (proved by the not yet published FUTURE trial, presented at AHA 2016 and ESC 2018). FFR and iFR and supportive trials [11] should be clinically ignored as should be the ORBITA trial [12]. These trials

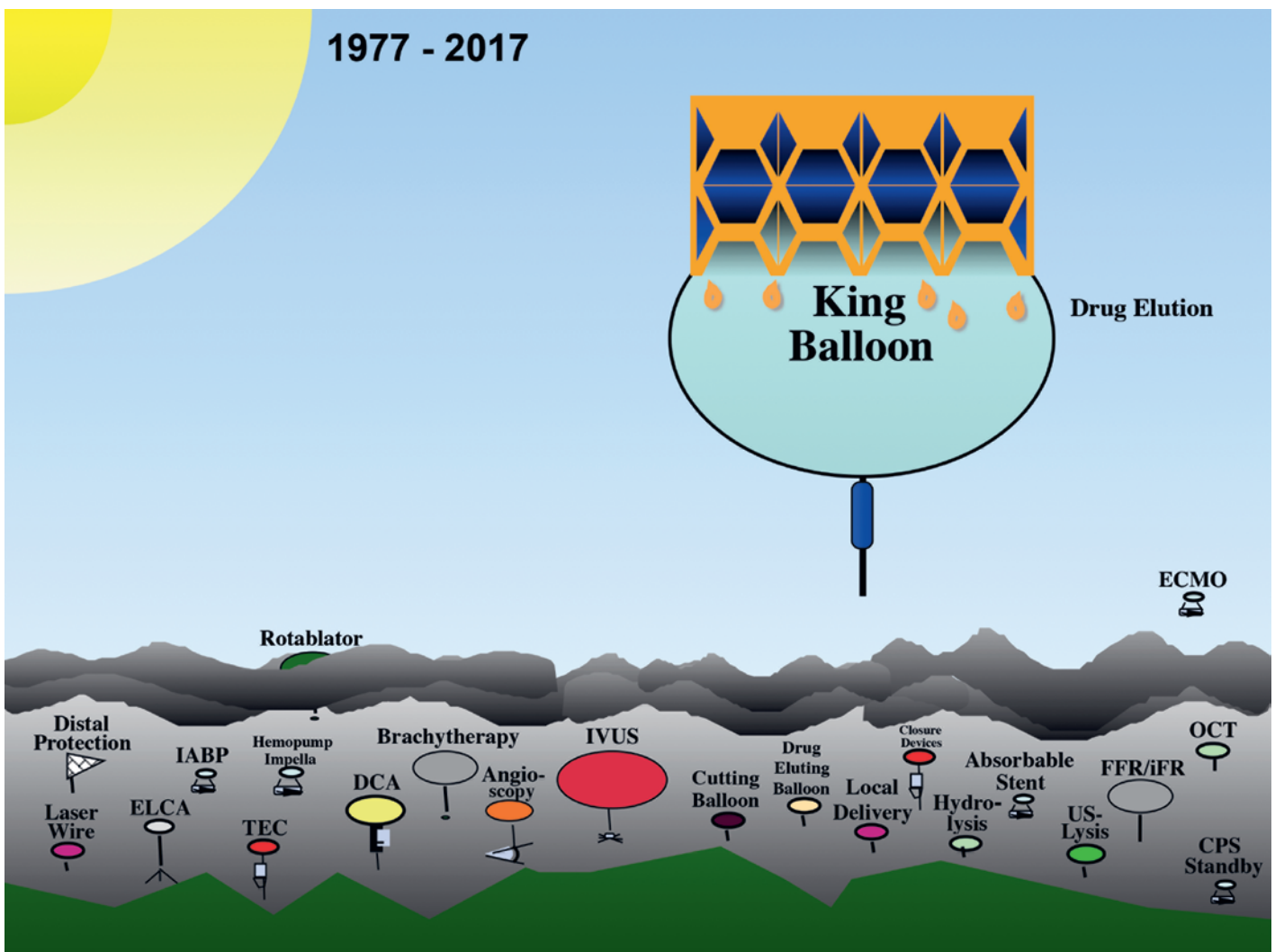


Figure 2: Summary pictogram of the technical evolution of percutaneous coronary intervention in its first 40 years.

The initial dilatation balloon has been crowned as King Balloon by the stent, which later was modified to elute drugs reducing restenosis. Other devices have either never made it into the sunlight or emerged briefly to then return below the clouds. Extracorporeal membrane oxygenation (ECMO) can save an occasional life in a busy catheterisation laboratory and therefore represents an exception. Rotablation may solve the very rare problem of a circumferentially calcified lesion resisting balloon passage or cracking with a modern low profile balloon tolerating 40 bar or more of dilation pressure.

Abbreviations: CPS: cardiopulmonary support; DCA: directional coronary atherectomy; ELCA: excimer laser coronary angioplasty; FFR/iFR: fractional flow reserve/instantaneous wave-free ratio; IABP: intraaortic balloon pump; IVUS: intravascular ultrasound; OCT: optical coherence tomography; TEC: transluminal endarterectomy catheter; US: ultrasound.

claim that dilating a mild lesion is more dangerous than leaving it untouched and ignoring the risk of lesion progression and abrupt closure due to plaque rupture. The latter risk may well be only 1% per year, but modern PCI to such a lesion carries only a comparably low risk in the first year, including during the intervention, but a much smaller risk in the subsequent years. Hence, the money seems to be better invested in a stent than in costly assessment with FFR or iFR. In parentheses, in the ORBITA trial, virtually everybody had undergone PCI at the end of the short 6-week follow-up [13]. The FAME-2 trial [11], pursuing the idea of the DEFER trial [10], confirmed the value of PCI, albeit not expressly. It showed that, in patients with a pathological FFR, abstaining from PCI leads to a high rate of return for PCI. That is hardly surprising. After all, the patients came for PCI the first time, PCI was withheld, so the patients come back. Somewhat illogically, the authors used the fact that the patients with a pathological FFR undergoing PCI have a similar outcome to that

of the patients with a nonpathological FFR and conservative treatment to justify to abstaining from PCI in the latter. The authors completely ignore the fact that the patients with a normal FFR also have an, admittedly smaller, risk of subsequent events that could and most probably would be reduced by PCI.

A similarly overall patient-unfriendly development was the upsurge of the radial approach to PCI or coronary angiography. Having been advertised since the late 1990s as a technique avoiding puncture site problems and allowing early mobilisation, the more intricate radial access found only a few followers. This changed after publication of a randomised study attesting a better clinical outcome with the radial approach than with the femoral approach in patients with acute coronary syndromes [14]. Intuitively, as with the FFR and ORBITA data, this does not make sense. Particularly in acute myocardial infarction jeopardising a large territory, every minute to coronary recanalisation counts and the femoral approach saves time overall. Scrutiny of the results shows that the difference came about exclusively in centres that already had adopted the radial approach as their default technique and pertained only to patients with a non-ST-segment elevation myocardial infarction. The fact that now not only PCIs in skilled centres, but virtually all PCIs around the world tend to be approached via the radial artery complicates logistics in catheterisation laboratories, costs thousands of radial arteries that (mostly silently) occlude after such interventions, increases cost, and probably also loses muscle in PCI for acute myocardial infarction. Yes, inguinal haematomas are avoided and patients enjoy immediate mobilisation (not really in acute coronary syndromes). But is this really worth the price?

It can only be hoped, but is far from certain, that FFR and the radial approach will eventually be relegated to below the cloud (fig. 2).

References

The full list of references is included in the online version of the article at <https://cardiovascmed.ch/en/article/doi/cvm.2018.00589/>

Correspondence:

Bernhard Meier, MD
Senior consultant and
professor of cardiology
Cardiovascular Department
University Hospital Bern
CH-3010 Bern
[bernhard.meier\[at\]insel.ch](mailto:bernhard.meier[at]insel.ch)

Take-home messages

- 1 Percutaneous coronary intervention (PCI) probably represents the most important contribution to world medicine of all time coming out of Switzerland.
- 2 The basic principle of PCI has remained unchanged since the world's first procedure performed by Andreas Grüntzig on 16 September 1977 at the University Hospital of Zurich, Switzerland (at the time called the Kantonsspital), but the contribution of the coronary stent (first implanted by Jacques Puel in Toulouse, France, on 29 March 1986) can be regarded as the icing on the cake.
- 3 The most important derivatives of PCI are transarterial aortic valve implantation and patent foramen ovale closure, although the latter preceded PCI by a couple of years in its form of atrial septal defect closure.
- 4 Additional future substantial break-throughs in PCI are unlikely as the technique has about 95% perfect success, a level rarely bettered in medicine.
- 5 Improved prevention decreases the prevalence of coronary artery disease and the need for PCI, but this is more than compensated for by the increasing average age of our population.